

2024-01-11

Equine anatomy with body painting: a model for the learning of topographic anatomy

José Miguel Velásquez Salazar
Universidad de Antioquia, jomiguel411@usp.br

Alejandro Mira Montoya
Universidad de Antioquia, alejandro.miram@udea.edu.co

Lynda Jhailú Tamayo-Arango
Universidad de Antioquia, lynda.tamayo@udea.edu.co

Follow this and additional works at: <https://ciencia.lasalle.edu.co/mv>

Citación recomendada

Velásquez Salazar JM, Mira Montoya A y Tamayo-Arango LJ. Equine anatomy with body painting: a model for the learning of topographic anatomy. Rev Med Vet. 2024;(48):. doi: <https://doi.org/10.19052/mv.vol1.iss48.9>

This Artículo de investigación is brought to you for free and open access by the Revistas científicas at Ciencia Unisalle. It has been accepted for inclusion in Revista de Medicina Veterinaria by an authorized editor of Ciencia Unisalle. For more information, please contact ciencia@lasalle.edu.co.

Equine anatomy with body painting: a model for the learning of topographic anatomy

José Miguel Velásquez-Salazar^{1,2}, Alejandro Mira-Montoya^{2,3},
Lynda Jhailú Tamayo-Arango^{2,4}

Abstract

The teaching of anatomy faces new challenges due to the decrease in the number of hours dedicated to this course in the current curricula worldwide, and because today's students demand new methodologies and strategies that make learning more didactic, effective, and applicable to real professional needs. The body painting technique is a method that has been used for several years in human anatomy teaching, which has recently begun to be used in veterinary anatomy teaching. This article describes the elaboration of a horse's live anatomical model by students of the veterinary anatomy course using body painting, within the "Exhibition and Contest of Anatomical Models, a six-monthly event held at the Faculty of Agrarian Sciences of the University of Antioquia (Medellín, Colombia). The model was made to show the academic community an alternative way of approaching topographic and surface anatomy with an applied focus through a more didactic and understandable methodology for the student. This article also shows the surface anatomy of various horses' body systems through the body painting technique. This learning methodology has great acceptance among students and is currently used within the practices of the new curriculum of the Veterinary Anatomy course at the University of Antioquia.

Keywords: Equine anatomy, undergraduate education, body painting, veterinary education

* Artículo de Reporte de caso.

1 Department of Surgery, Faculdade de Medicina Veterinária e Zootecnia, Universidade de São Paulo, Av. Prof. Orlando Marques de Paiva 87, São Paulo, Brazil
✉ jomiguel411@usp.br
ORCID <https://orcid.org/0000-0002-1246-1504>

2 Research group CIBAV, Escuela de Medicina Veterinaria, Facultad de Ciencias Agrarias, Universidad de Antioquia, Calle 70 No. 52-21, Medellín, Colombia

3
✉ alejandro.miram@udea.edu.co
ORCID <https://orcid.org/0000-0002-2313-3506>

4
✉ lynda.tamayo@udea.edu.co
ORCID <https://orcid.org/0000-0003-1751-3198>

Anatomía equina con pintura corporal: un modelo para el aprendizaje de la anatomía topográfica

Resumen

La enseñanza de la anatomía enfrenta nuevos desafíos debido a la disminución del número de horas dedicadas a esta materia en los planes de estudio vigentes a nivel mundial, y porque los estudiantes de hoy demandan nuevas metodologías y estrategias que hagan el aprendizaje más didáctico, efectivo y aplicable a las necesidades reales de los profesionales. La técnica de pintura corporal es un método que se ha utilizado durante varios años en la enseñanza de la anatomía humana y recientemente se ha comenzado a

Cómo citar este artículo: Cómo citar este artículo: Salazar, J. M. V., Mira-Montoya, A. & Tamayo-Arango, L.J. (2024). Equine anatomy with body painting: a model for the learning of topographic anatomy. *Rev Med Vet.* 2024;(48) e1489. <https://doi.org/10.19052/mv.vol1.iss48.9>

utilizar en la enseñanza de la anatomía veterinaria. Este artículo describe la elaboración de un modelo anatómico vivo de un caballo por parte de estudiantes de la asignatura de anatomía veterinaria utilizando pintura corporal, dentro de la “Exposición y Concurso de Modelos Anatómicos, evento semestral realizado en la Facultad de Ciencias Agrarias de la Universidad de Antioquia (Medellín, Colombia). El modelo se realizó para mostrar a la comunidad académica una forma alternativa de abordar la anatomía topográfica y de superficie con un enfoque aplicado, a través de una metodología más didáctica y comprensible para el estudiante. Este artículo también muestra la anatomía superficial de varios sistemas corporales de caballos a través de la técnica de pintura corporal. Esta metodología de aprendizaje tiene gran aceptación entre los estudiantes y actualmente se utiliza dentro de las prácticas del nuevo plan de estudios de la asignatura de Anatomía Veterinaria de la Universidad de Antioquia.

Palabras clave: anatomía equina, educación universitaria, pintura corporal, educación veterinaria

INTRODUCTION

Basic medical sciences, such as anatomy, represent the foundations of medicine, both human and animal. Anatomy provides the basics that allow the understanding of other basic sciences, and it is essential for clinical and surgical practice (1-3). However, teaching anatomy in the 21st century is challenging, as the number of hours devoted to it in the curricula has been drastically reduced (4, 5), and there is a trend to reduce or eliminate the use of cadavers, especially because of the costs involved in their maintenance; some institutions have even closed their laboratories (6, 7). The traditional way of teaching anatomy through lectures and prosections may be an insufficient method. It is necessary to include active didactic strategies so that students can appropriate anatomical knowledge, awaken their interest in the subject, and generate long-term learning (8, 9).

Body painting is a widely used technique within the human anatomy teaching curricula (10-14), and it has recently begun to be used in veterinary medicine due to its effectiveness in optimizing the learning of surface anatomy by showing the arrangement of the different organs and structures in the living being in a more didactic and understandable way. This has been done in veterinary medicine using synthetic models and painting the surface structures (15), but also using body painting on living animals, being painted by the students or faculty (9, 16). It is challenging for students to get a realistic notion of the size and position of the organs in the living animal if they only see dissected cadavers in the laboratory. Also, it is difficult to maintain cadavers of adult cows or horses in veterinary anatomy laboratories, because of their large size. Therefore, the students will not always be able to see directly, for example, the space that the rumen occupies within the abdominal cavity in the cow or the colon and cecum in the equine (16).

The Veterinary Anatomy course at the University of Antioquia is a one-semester course in which students learn the anatomy of the different body systems of domestic animals through theoretical and practical

lessons, which are complemented with dissection activities and applied anatomy such as body painting. During the course, the students also make a didactic model for learning anatomy and present it to the university community at the end of the semester.

This article describes the elaboration of a horse's live anatomical model through body painting by second-semester veterinary anatomy students, within the framework of the Exhibition and Contest of Anatomical Models held every semester at the Faculty of Agricultural Sciences of the University of Antioquia (Medellín, Colombia), to show the academic community a novel way of approaching topographic and surface anatomy through a more didactic and understandable methodology for the student. The model focused on the location of the different anatomical structures in the living animal and their clinical application. This article also shows the main structures of the horses' surface anatomy through the body painting technique.

MATERIAL AND METHODS

This work was approved by the ethics committee for animal experimentation at the University of Antioquia. An equine with a docile temperament, white in color and a medium body condition (3/5) was chosen so that the colors and bone accidents were better highlighted and the identification of the structures through palpation was easier. The work was conducted in the facilities of the Veterinary Hospital of the University of Antioquia and painted by two students from the veterinary anatomy course with the orientation of a veterinarian professor. A previous theoretical preparation was made on the topographic anatomy of the equine with the elaboration of schemes and diagrams as guides for the practical work. Additionally, the most common semiological, clinical, and surgical procedures in horses were investigated, so that they served to apply anatomical knowledge.

Before proceeding to paint, the animal was washed with water and pH-neutral soap to remove impurities

and facilitate the adherence of the paint, in addition to improving the aesthetics of the final appearance. To facilitate the painting process and in areas where the animal's fur was longer or dense, the entire area to be painted was trimmed with a special machine for animals (Oster® ShearMaster®). The paint used was vinyl (water-based) mixed with a pH-neutral liquid soap, to avoid irritating the animal's skin and to facilitate the removal of the paint after the lesson. At the beginning of the painting process, the edge of the structure or organ was demarcated, then its interior was painted

and, finally, an outline was made with black vinyl to highlight and differentiate the structures.

On the left side of the animal, the skeletal system was painted, including the nuchal ligament (Figure 1A) and on the right side of the animal, structures and organs of various systems were painted as follows: 1) in the neck: larynx and trachea, 2) in the thoracic cavity: lungs and heart, 3) in the abdominal cavity: colon, cecum, liver and right kidney; the lung auscultation area was also demarcated (Figure 1B). As a complement to the visual

Figure 1. Anatomical Model Presented in the Exhibition and Contest of Anatomical Models
Note: The skeletal system with the nuchal ligament was painted on the left side (A) and the visceral organs of the thoracic and abdominal cavities on the right side (B).



model, a list of semiological, clinical, and surgical procedures was made, so the assistants could select from a “menu” to receive an explanation based on anatomy, taking the structures painted on the animal as a reference. The procedures included were pulmonary and cardiac auscultation, thoracentesis, abdominocentesis, lateral laparotomy, nasogastric intubation, extraction of cerebrospinal fluid, injection sites, liver biopsy, and cecal trocarization.

Finally, the animal was washed with plenty of water, neutral soap, and a soft brush to remove all the paint. Throughout the day the animal had water and food available and was in an adequate facility protected from sunlight. In addition, there was a delimitation that separated the public from the animal to reduce stress and the probability of an accident. Subsequently, other body painting sessions were made to show various structures and body systems and create a photographic

archive of the topographic anatomy of the equine. The body regions, skeletal, muscular, digestive, and cardiovascular systems were painted.

RESULTS


An interactive model was obtained that allowed the participants to simply observe the anatomical structures painted on the horse and perceive the size and position of many organs, as well as request a particular explanation of various clinical procedures that could be chosen from the menu according to their interest. The students demonstrated and explained the procedures on the animal since various organ systems were painted. From the subsequent sessions of body painting, photographs of the body regions, skeletal, muscular, digestive, and cardiovascular systems were obtained (figures 2 to 6).

Figure 2. Regions of the Body Painted on the Left Side of a Horse



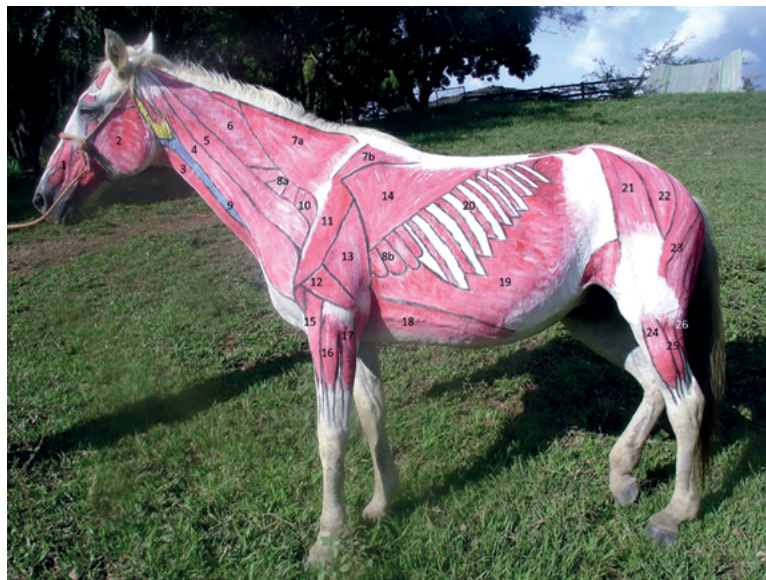Note: Parotid (1), laryngeal (2), jugular (3), ventral neck (4), lateral neck (5), dorsal neck (6), interscapular (7), prescapular (8), scapular (9), shoulder (10), brachial (11), tricipital (12), elbow (13), antebrachial (14), carpal (15), metacarpal (16), metacarpophalangeal (17), digital (18), thoracic vertebral (19), costal (20), sternal (21), xiphoid (22), umbilical (23), hypochondriacal (24), paralumbar fossa (25), lumbar (26), flank (27), inguinal (28), pelvic (29), coxal tuberosity (30), gluteal (31), trochanteric (32), perineal (33), femoral (34), knee (35), popliteal (36), crural (37), tarsal (38), metatarsal (39), metatarsophalangeal (40).

Figure 3. Skeletal System Painted in the Left Side of a Horse



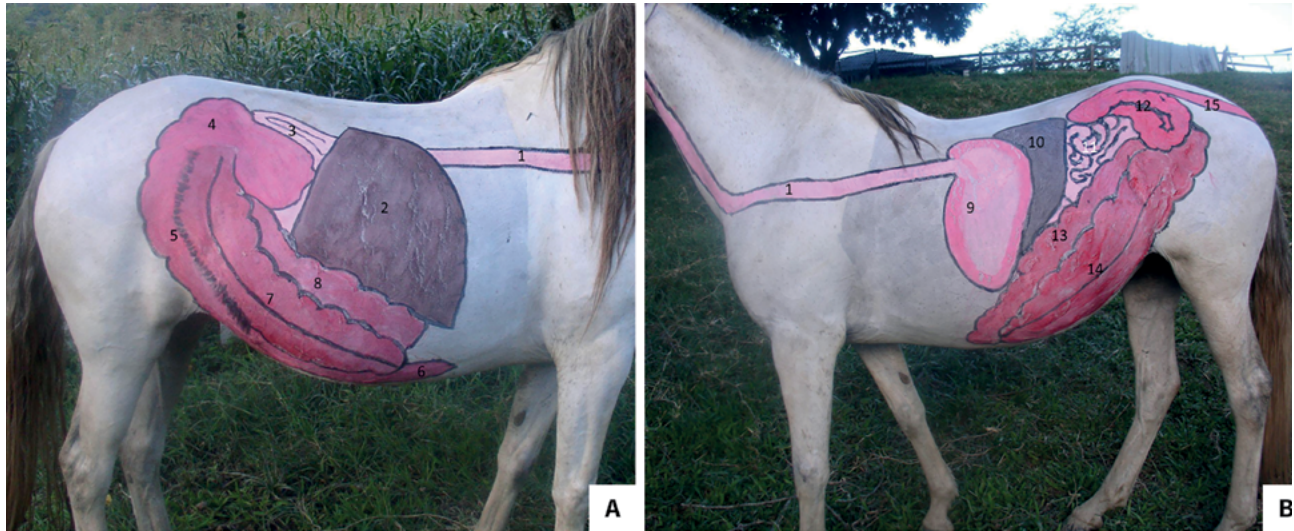
Note: Main bones: maxilla (1), mandibular (2), cervical vertebrae (3), funicular portion (4a) and laminar portion (4b) of the nuchal ligament, scapula (5), humerus (6), radius (7), ulna (8), carpal (9), manus (10-14), metacarpal (10), proximal sesamoidea (11), proximal phalange (12), media phalange (13), distal phalange (14), sternum (15), thoracic vertebrae (16), ribs (17), costal cartilage (18), lumbar vertebrae (19), coxal (20), femur (21), patellae (22), tibia (23), tarsal (24), pedis (25-29), metacarpal (25), proximal phalange (27), media phalange (28), distal phalange (29).

Figure 4. Muscular System Painted in the Left side of a Horse



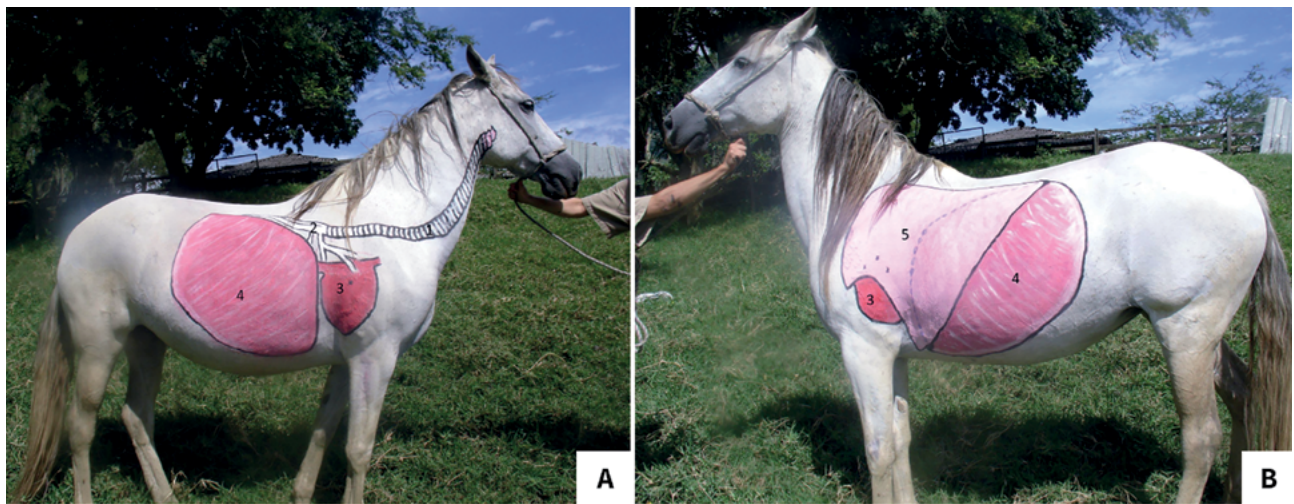
Note: Superficial muscles: facial muscles (1), masseter (2), sternocephalicus (3), brachiocephalicus (4), omotransversarius (5), splenius (6), trapezius pars cervicalis (7a) and pars thoracica (7b), serratus ventralis cervicis (8a) and thoracis (8b), jugular vein (9), supraspinatus (10), deltoideus (11), triceps brachii caput laterale (12) and caput longum (13), latissimus dorsi (14), extensor carpi radialis (15), extensor digitalis communis (16), ulnaris lateralis (17), pectoralis profundus (18), obliquus externus abdominis (19), intercostales externi (20), tensor fasciae latae (21), gluteus superficialis (22), biceps femoris (23), extensor digitalis longus (24), extensor digitalis lateralis (25), gastrocnemius (26).

Figure 5. Digestive System Painted on the Right (A) and Left (B) Side of a Horse



Note: Esophagus (1), liver (2), duodenum (3), base of the cecum (4), body of the cecum (5), apex of the cecum (6), right ventral colon (7), right dorsal colon (8), stomach (9), spleen (10), jejunum (11), descending colon (12), left dorsal colon (13), left ventral colon (14), rectum (15).

Figure 6. Cardiorespiratory System Painted on the Right (A) and Left (B) Side of a Horse



Note: Trachea (1), bronchi (2), heart (3), diaphragm in all its extension (4), left lung (5). The diaphragm was painted in all its extension, from the insertion in the costal arch (caudal) to the diaphragmatic cupola (cranial)

DISCUSSION

In recent years, the teaching of both human and veterinary anatomy has been changing and adapting to the current needs of students, through the diversification

of didactic strategies, as a complement to the traditional teaching methods of anatomy based on lectures and the use of cadavers. The benefits of direct study in cadavers and dissection are undeniable (17, 18); however, they must be complemented with new teaching

modalities and technologies that allow for improving the optimization of anatomy learning (2, 19). Among the new modalities for teaching anatomy are plastination, computational models, scale models in different materials, the use of diagnostic imaging tools, 3D tools, and more recently live anatomy models (4, 19-22).

There are several didactic strategies for teaching topographic anatomy, such as body painting. Its use for human anatomy teaching was described and published for the first time by Op Den Akker et al (23). Since then, the technique has been widely used in human anatomy courses, with a high level of satisfaction and perception of better long-term recall of knowledge by students (6, 10, 11, 24-26). Some experiences in surface veterinary anatomy have also been reported with the use of live animals covered with a garment showing several anatomical structures (27) and there are only two reports using body painting in veterinary anatomy, one in which the faculty painted the animal and explained the anatomy (9) and one where the students themselves painted the animals (16). In the last one, the students showed an improvement in performance on a test carried out before the body painting session, compared to a test immediately after and 7 weeks after the body painting session in horses and cattle. In the first study (6), the authors had similar results of improvement in student recall of the anatomical structures; however, in this study, the animals were painted by the faculty and the test after the body painting session was performed immediately and 1 hour after observing the painted animal. Therefore, it was not possible to assess long-term knowledge retention and kinesthetic skills because the activity of painting structures was not done by the students.

Body painting is shown as a good alternative that allows providing a first approach to surface anatomy and as a complement to the teaching of technical skills (28), and in the case of veterinary medicine, it may represent the first contact with live animals in the students' professional career—it is very common when the students have lived in the city all their life and have not had any contact with cows and horses before. Body

painting reduces cognitive load; therefore, anatomical information could be processed more easily by working memory which may increase knowledge retention and recall (28, 29). In addition, different types of learners could do better due to the method's multifunctionality: the students read instructions (auditory), actively paint (kinesthetics), use touch perception (tactile) and experiment visual stimuli (visual) (28, 29).

As an active way of learning, with its advantages, we incorporate body painting into the course of veterinary anatomy as two sessions for students to paint cows or horses (locomotor and nervous system for the first session, splanchnology for the second session) (16). It is important that students themselves paint, to attain the full learning experience, and to enjoy the activity, as in other studies, the students perceived body painting sessions as fun and motivating (6, 9, 16, 30).

Body painting is shown as an optimal alternative to complement traditional teaching methods, with the advantage of being inexpensive and easy to implement compared to the use of cadavers and anatomy software (6, 24, 29, 31), with some possible disadvantages as the long working sessions, which are not always possible within the available class times, and the difficulty concerning the nudity among students that is necessary for human medicine (24, 25), which is not the case in veterinary medicine as the practice subjects are animals. Other limitations of the technique could be the possible environmental contamination due to discarding vinyl paint when bathing the animal after the body painting session; also, the risk of injuries when inexperienced students try to handle nervous or aggressive animals. Therefore, we strongly recommend working with docile animals or doing a slight sedation, under the direct supervision of a veterinarian.

It has been shown that the fact of painting the anatomical structures on the living animal helps the student to remember them for a longer time, in addition to better understanding the arrangement and size that they occupy, regarding some landmarks (9, 16). Another advantage of body painting compared to cadavers is

that it allows the anatomy to be shown under natural movements (24, 30). Other authors did not find a better performance in short- or long-term examinations after studying the surface anatomy in a horse-painted model; however, enhanced confidence levels were detected (15). We think that the learning process is more significant if the students can have a kinesthetic experience by identifying the landmarks and painting themselves the animals, compared to observing a model or an actual animal already painted.

The anatomical model was very well received and accepted by students and the professors, and one of the aspects to highlight in this didactic model was peer learning because the model was prepared and explained by the same students of the anatomy course to their classmates (peer learning), as well as students of other levels of training (near-peer learning), which has been seen to favor autonomy, self-learning and an improvement in knowledge on the part of the student who teaches, as well as their peers (32). In addition, without the limitation of feeling ashamed for asking a question that they might consider irrelevant or unnecessary, as it commonly happens when they are in a classroom in front of a teacher.

This technique has been widely used as a learning methodology in veterinary medicine, with high efficiency and acceptance by students, as a tool that allows the development of communication skills, improves knowledge, and allows learning in a closer and more friendly way when feeling more comfortable solving doubts and learning from colleagues who see them as equals (33, 34).

The study of surface anatomy has been gaining importance in the curricula of several medical and veterinary universities because it connects basic gross anatomy and clinical practice, generating the basis of clinical examination (5). The body painting technique can be used to cover many topics of surface anatomy and clinical anatomy (28, 30), as described in this article, with the inclusion of several clinical procedures of importance in veterinary practice.

It is important to highlight that in veterinary medicine we must prioritize the welfare of the individuals who are being painted. For this, it should be highlighted that this type of activity must be previously authorized by an animal ethics committee and must be carried out in a spacious and safe place, where the animal can always be protected from sun and rain, and always have access to food and water. Regarding the instruments to perform the technique, water-based vinyl paints must be used and mixed with neutral pH liquid soap to avoid any type of allergic reaction on the animal's skin, in addition to allowing easy removal and causing the least discomfort to the animal. Finally, the activity must always be carried out under the supervision of a veterinarian who guarantees the welfare of the animal at all times.

CONCLUSIONS

Based on our experience with equine body painting, we consider it to be an ideal technique to complement traditional classes within anatomy courses. It awakens the interest of students by allowing them to be self-taught because they place the structures in the animal themselves, which improves long-term recall. In addition, thanks to the activity carried out, it was evident that it brings benefits by preparing the student for more advanced disciplines by allowing interdisciplinarity between topographic anatomy and clinical practice.

ACKNOWLEDGMENTS

We appreciate the collaboration of the Universidad de Antioquia for the facilities and animals that it made available to make the models.

REFERENCES

1. Tibrewal S. The anatomy knowledge of surgical trainees: The trainer's view. *Bull R Coll Surg Engl.* 2006;88(7):240-2. <https://doi.org/10.1308/147363506x113857>

2. Turney BW. Anatomy in a modern medical curriculum. *Ann R Coll Surg Engl.* 2007;89(2):104-7. <https://doi.org/10.1308/003588407X168244>
3. Caswell FR, Venkatesh A, Denison AR. Twelve tips for enhancing anatomy teaching and learning using radiology. *Med Teach.* 2015;37(12):1067-71. <https://doi.org/10.3109/0142159X.2015.1029896>
4. Ganguly P. Teaching and Learning of Anatomy in the 21st Century: Direction and the Strategies. *Open Med Educ J.* 2010;3(1):5-10.
5. Naidoo N, Akhras A, Banerjee Y. Confronting the Challenges of Anatomy Education in a Competency-Based Medical Curriculum During Normal and Unprecedented Times (COVID-19 Pandemic): Pedagogical Framework Development and Implementation. *JMIR Med Educ.* 2020 Oct;6(2):e21701. <https://doi.org/10.2196/21701>
6. Finn GM, McLachlan JC. A qualitative study of student responses to body painting. *Anat Sci Educ.* 2010;3(1):33-8. <https://doi.org/10.1002/ase.119>
7. Abdalla S. The role of anatomy demonstration for surgical trainees. *Bull R Coll Surg Engl.* 2011;93(2):60-2. <https://doi.org/10.1308/147363511x554528>
8. Plendl J, Bahramsoltani M, Gemeinhardt O, Hünigen H, Käbmeyer S, Janczyk P. Active participation instead of passive behaviour opens up new vistas in education of veterinary anatomy and histology. *J Vet Med Ser C Anat Histol Embryol.* 2009;38(5):355-60. <https://doi.org/10.1111/j.1439-0264.2009.00954.x>
9. Senos R, Ribeiro MS, De Souza Martins K, Pereira LV, Mattos MF, Kfoury JR, et al. Acceptance of the bodypainting as supportive method to learn the surface loco motor apparatus anatomy of the horse. *Folia Morphol.* 2015;74(4):503-7. <https://doi.org/10.5603/FM.2015.0023>
10. Nanjundaiah K, Chowdapurkar S. Body-painting: A tool which can be used to teach surface anatomy. *J Clin Diagnostic Res.* 2012;6(8):1405-8. <https://doi.org/10.7860/JCDR/2012/4700.2370>
11. Goulart L, Merini LR, Pereira EN. A pintura corporal como recurso metodológico para o ensino da anatomia humana para estudantes de medicina da Universidade Federal do Amazonas, Brasil. *Lect Educ Física Deport.* 2015;(209).
12. Jariyapong P, Punsawad C, Bunratsami S, Kongthong P. Body painting to promote self-active learning of hand anatomy for preclinical medical students. *Med Educ Online.* 2016;21:30833. <https://doi.org/10.3402/meo.v21.30833>
13. Bennett CC. Anatomic body painting as a teaching tool in physician assistant education. *Med Sci Educ.* 2018;28:525-32. <https://doi.org/10.1007/s40670-018-0581-y>
14. Finn GM. Current perspectives on the role of body painting in medical education. *Adv Med Educ Pract.* 2018;9(11):701-6. <http://dx.doi.org/10.2147/AMEP.S142212>
15. Bietzk E, Weller R, Simons V, Channon SB. Anatomy teaching, a “model” answer? Evaluating “Geoff”, a painted anatomical horse, as a tool for enhancing topographical anatomy learning. *Anat Sci Educ.* 2019;12(5):S29-40. <https://doi.org/10.1002/ase.1823>
16. Tamayo-Arango LJ, Mejía-Durango MA. Body painting of the horse and cow to learn surface anatomy. *J Vet Med Educ.* 2020;47(4):395-401. <https://doi.org/10.3138/JVME.0818-094R1>
17. Ghosh SK. Cadaveric dissection as an educational tool for anatomical sciences in the 21st century. *Anat Sci Educ.* 2017;10(3):286-99. <https://doi.org/10.1002/ase.1649>
18. Gummery E, Cobb KA, Mossop LH, Cobb MA. Student perceptions of veterinary anatomy practical classes: A longitudinal study. *J Vet Med Educ.* 2018;45(2):163-76. <https://doi.org/10.3138/jvme.0816-132r1>
19. Massari CHDAL, Schoenau LSF, Cereta AD, Miglino MA. Tendências do ensino de anatomia animal na graduação de medicina veterinária. *Rev Grad USP.* 2018;3(2):25. <https://doi.org/10.11606/issn.2525-376x.v3i2p25-32>
20. McLachlan JC, Regan De Bere S. How we teach anatomy without cadavers. *Clin Teach.* 2004;1(2):49-52. <https://doi.org/10.1111/j.1743-498x.2004.00038.x>
21. Latorre RM, García-Sanz MP, Moreno M, Hernández F, Gil F, López O, et al. How useful is plastination in learning anatomy? *J Vet Med Educ.* 2007;34(2):172-6. <https://doi.org/10.3138/jvme.34.2.172>
22. Estai M, Bunt S. Best teaching practices in anatomy education: A critical review. *Ann Anat.* 2016;208:151-7. <https://doi.org/10.1016/j.aanat.2016.02.010>

23. Op Den Akker JW, Bohnen A, Oudegeest WJ, Hillen B. Giving color to a new curriculum: Bodypaint as a tool in medical education. *Clin Anat.* 2002;15(5):356-62. <https://doi.org/10.1002/ca.10049>
24. Bennett C. Anatomic body painting: Where visual art meets science. *J Physician Assist Educ.* 2014;25(4):52-4. <https://doi.org/10.1097/01367895-201425040-00009>
25. Aka JJ, Cookson NE, Hafferty FW, Finn GM. Teaching by stealth: Utilising the hidden curriculum through body painting within anatomy education. *Eur J Anat.* 2018;22(2):173-82.
26. Carrasco-Molinillo C, Ribelles-García A, Gomar DA, Pérez-Arana G, Prada-Oliveira JA. The teaching of surface anatomy by body painting. *Int J Morphol.* 2019;37(3):912-6. <https://doi.org/10.4067/S0717-95022019000300912>
27. Braid F, Williams SB, Weller R. Design and validation of a novel learning tool, the “Anato-Rug,” for teaching equine topographical anatomy. *Anat Sci Educ.* 2012;5(5):256-63. <https://doi.org/10.1002/ase.1295>
28. Finn GM. Using body painting and other art-based approaches to teach anatomy. In: Chan LK, Pawlina W, editors. *Teaching anatomy: A practical guide.* Cham: Springer International Publishing; 2015. p. 155-64. https://doi.org/10.1007/978-3-319-08930-0_18
29. Cookson NE, Aka JJ, Finn GM. An exploration of anatomists’ views toward the use of body painting in anatomical and medical education: An international study. *Anat Sci Educ.* 2018;11(2):146-54. <https://doi.org/10.1002/ase.1698>
30. McMenamin PG. Body painting as a tool in clinical anatomy teaching. *Anat Sci Educ.* 2008;1(4):139-44. <https://doi.org/10.1002/ase.32>
31. Finn GM. Twelve tips for running a successful body painting teaching session. *Med Teach.* 2010;32(11):887-90. <https://doi.org/10.3109/0142159X.2010.507708>
32. Evans DJR, Cuffe T. Near-peer teaching in anatomy: An approach for deeper learning. *Anat Sci Educ.* 2009;2(5):227-33. <https://doi.org/10.1002/ase.110>
33. Spielman S, Hughes K, Rhind S. Development, evaluation, and evolution of a peer support program in veterinary medical education. *J Vet Med Educ.* 2015;42(3):176-83. <https://doi.org/10.3138/jvme.1114-115R>
34. Bell CE, Rhind SM, Stansbie NH, Hudson NPH. Getting started with peer-assisted learning in a veterinary curriculum. *J Vet Med Educ.* 2017;44(4):640-8. <https://doi.org/10.3138/jvme.0216-047R>