

2024-01-11

Conjunctival Hemangiosarcoma in a Female Dog: Case Report

Felipe Gaia de Sousa

Universidade Federal de Minas Gerais, fgaias@outlook.com

Suzane Lilian Beier

Universidade Federal de Minas Gerais, suzanelb@yahoo.com.br

José Antônio da Cruz Neto

Pontifícia Universidade Católica de Minas Gerais, revistamedicinaveter@lasalle.edu.co

Natália Fagundes

Universidade Federal de Minas Gerais, revistamedicinaveter@lasalle.edu.co

Isaac Scherre Lubiana

Pontifícia Universidade Católica de Minas Gerais, isaacscherre@hotmail.com

See next page for additional authors

Follow this and additional works at: <https://ciencia.lasalle.edu.co/mv>



Part of the [Agriculture Commons](#), [Animal Sciences Commons](#), and the [Veterinary Medicine Commons](#)

Citación recomendada

Gaia de Sousa F, Beier SL, da Cruz Neto JA, Fagundes N, Scherre Lubiana I y de Andrade AC. Conjunctival Hemangiosarcoma in a Female Dog: Case Report. Rev Med Vet. 2024;(48):. doi: <https://doi.org/10.19052/mv.vol1.iss48.8>

This Reporte de casos is brought to you for free and open access by the Revistas científicas at Ciencia Unisalle. It has been accepted for inclusion in Revista de Medicina Veterinaria by an authorized editor of Ciencia Unisalle. For more information, please contact ciencia@lasalle.edu.co.

Conjunctival Hemangiosarcoma in a Female Dog: Case Report

Autor

Felipe Gaia de Sousa, Suzane Lilian Beier, José Antônio da Cruz Neto, Natália Fagundes, Isaac Scherre Lubiana, and Alaine Cristina de Andrade

Conjunctival Hemangiosarcoma in a Female Dog: Case Report

Felipe Gaia de Sousa¹, Suzane Lilian Beier¹, José Antônio da Cruz Neto²,
Natália Fagundes¹, Isaac Scherre Lubiana², Alaine Cristina de Andrade³

Abstract

Hemangiosarcomas are tumors of mesenchymal origin, potentially deleterious, associated with areas of high vascularization. Tumor progression and growth are associated with these tumors' ability to retain blood and give rise to tortuous blood vessels. They have a vast metastatic capacity, often occurring in organs such as the spleen, liver, and aorta artery. However, other sites may be affected, although less frequently, such as the third eyelid and the conjunctiva and cutaneous regions. This article aims to report the case of an 8-year-old female dog with a history of conjunctival hemangiosarcoma, in the medial region of the left eye, with a hemorrhagic appearance. The animal was submitted to the surgical procedure of enucleation after the involvement of the surgical margins in a previous histopathological examination.

Keywords: Endothelial tumors; malignant aspect; mesenchymal tumors; ocular conjunctiva; oncology.

Hemangiosarcoma conjuntival en una perra: reporte de caso

Resumen

Los hemangiosarcomas son tumores de origen mesenquimatoso, potencialmente deletéreos, asociados a áreas de alta vascularización. La progresión y el crecimiento del tumor están asociados con la capacidad de estos tumores para retener sangre y dar lugar a vasos sanguíneos tortuosos. Estos tumores tienen una gran capacidad metastásica, presentándose a menudo en órganos como el bazo, el hígado y la arteria aorta. Sin embargo, otros sitios pueden verse afectados, aunque con menor frecuencia, como el tercer párpado, la conjuntiva y las regiones cutáneas. El objetivo de este artículo es reportar el caso de una perra de 8 años de edad con antecedente de hemangiosarcoma conjuntival, en la región medial del ojo izquierdo, de aspecto hemorrágico. El animal fue sometido al procedimiento quirúrgico de enucleación tras la afectación de los márgenes quirúrgicos en un examen histopatológico previo.

Palabras clave: tumores endoteliales; aspecto maligno; tumores mesenquimales; conjuntiva ocular; oncología.

* Artículo de Reporte de caso.

1 Department of Veterinary Clinic and Surgery, School of Veterinary Medicine, Federal University of Minas Gerais – UFMG, Brazil

✉ fgaias@outlook.com

2 Veterinarian – Pontifical Catholic University of Minas Gerais – PUC Minas, Brazil

3 Formiga University Center, Brazil

Cómo citar este artículo: Sousa FG, Beier SL, Neto JAC, Fagundes N, Lubiana IS, Andrade AC. Conjunctival Hemangiosarcoma in a Female Dog: Case Report. Rev Med Vet. 2024;(48) e1486. <https://doi.org/10.19052/mv.vol1.iss48.8>

INTRODUCTION

Hemangiosarcomas (HSA) are malignant mesenchymal tumors, with high metastatic capacity, and they derive from endothelial cells (1-3). The origin of HSA is associated with tissues and organs that have rich vascularization and can spread through the hematogenous route (4). According to Soares et al. (5), the prevalence of HSA is almost 67%. The spreading through the blood vessels may be one of the factors that contribute to the aggressivity of those tumors (4). The origin of HSA is still uncertain (6), although they mention the possibility of endothelial mutations and the discontinuation of hemangioblastic differentiation (1, 7, 8).

The location of HSA is quite variable (3), although some organs are more often involved, such as the spleen, liver, kidneys, heart (especially right atrium), and lungs (3,9,10). It is important to emphasize that other organs and body tissues can be affected. However, there are reports that the occurrence in the splenic parenchyma exceeds the detection in other organs (5,7). According to Freitas et al. (7), the nictitating membranes and the conjunctiva and cutaneous regions are places with infrequent occurrence.

The growth pattern of these tumors is significant, with high progression and large consequences. HSAs could induce tortuous and irregular neovascularizations to drain larger amounts of blood and progress easily (7). Faced with the increase in blood flow and stasis, the endothelial wall becomes fragile and susceptible to ruptures. This article aims to describe the clinical case and associated clinical-pathological aspects of a female dog diagnosed with primary conjunctival hemangiosarcoma in its left eye.

Case Description

A female dog, 8 years old, 10 kg, mixed breed, spayed, dewormed and vaccinated, was seen at a veterinary clinic in the city of Itaúna/MG, Brazil, with a history of an eye lesion with an irregular appearance and reddish

color. The lesion was close to the iris and, according to the owner, it had been growing significantly and at times bleeding. On physical examination, heart rate was 124 bpm, respiratory rate was 26 bpm, temperature was 38.4°C, normal colored mucous membranes, and lymph nodes were without significant changes in size, volume or morphology. There were no changes in the other organic regions evaluated.

However, with the changes in the ocular region, a more careful ophthalmological evaluation was conducted. The right eye (RE) had pupillary, consensual, and menace reflexes present. The regions of the eyelids, bulb, cornea, anterior chamber, iris, pupil, lens, fundus and vitreous also showed no changes. There was no secretion in the RE. The 1% fluorescein and Jones tests were performed, and there were no ulcers or changes in the patency of the nasolacrimal duct. The left eye (LE) presented the same conditions, except for a hemorrhagic mass in the ocular conjunctiva, medial portion, close to the nictitating membrane.

In the presence of a lesion, tobramycin-based eye drops were prescribed (1 drop, every 3 hours, 10 days). It was suggested that the LE lesion should be scraped and sent for histopathological analysis. Blood samples were collected for laboratory tests (blood count and biochemistry), and the animal was sent for the surgical procedure of material collection.

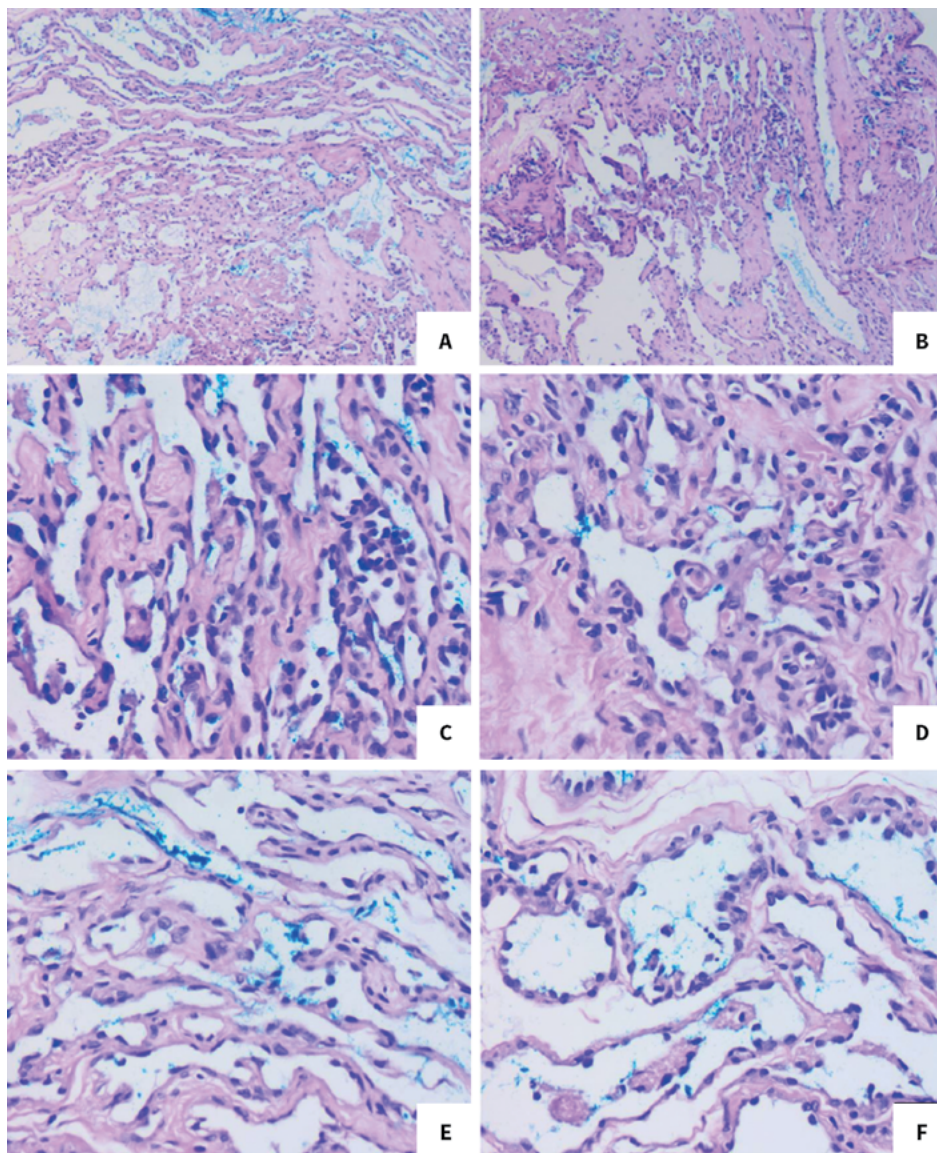
Considering that the laboratory results obtained were within the normal range and the patient was healthy, the animal was referred for surgery to remove the lesion in the conjunctival region. After surgical removal, the fragment was sent for histopathological analysis for possible diagnosis. Two irregular tissue fragments measuring together 0.8 x 0.2 x 0.2 cm of soft consistency were sent. The samples had a solid surface, with a homogeneous appearance, of a light brown color. After the material collection procedure, it was recommended to continue with tobramycin (same dosage, 10 days), dipyrone monohydrate 500 mg/ml (10 drops, PE, every 12 hours, 5 days), and to use an Elizabethan collar.

A microscopically, proliferation of neoplastic cells was observed, formed by vascular spaces, occupied by blood and delimited by immature endothelial cells. The process demonstrates poorly delimited, non-encapsulated growth and is supported by moderate fibrous connective tissue. The cells have unbounded cytoplasm, with nuclei ranging from ovoid to round, normochromic, and small nucleoli. Mild to moderate anisocytosis and

anisokaryosis. About one mitosis was observed in 10 higher power fields (400X; 2.37 mm²). The surgical margins were compromised and there was a diagnosis of hemangiosarcoma (Figure 1).

With a definitive diagnosis of HSA, a radiograph was performed in ventrodorsal projection to rule out the presence of metastases. The radiographic report did

Figure 1. Sample of the lesion in the ocular conjunctiva, HE (A-F). There is a proliferation of neoplastic cells, a presence of blood cells and immature endothelial cells. Presence of connective tissue, with variability in the size of the nuclei. Note the low number of mitoses (1 in 10 fields). Lesions suggestive of primary conjunctival hemangiosarcoma (400x; 2.37 mm²)



not present noteworthy alterations considering the canine thoracic architecture and morphology. There were no radiographic images suggestive of metastatic pulmonary nodules.

Based on the diagnosis of HSA in the conjunctival region and due to the compromise of the surgical margins, the patient's tutor was recommended to perform the enucleation. Hematological and biochemical tests were performed again to assess surgical risk, and the exams presented values within the normal range. The LE enucleation procedure was a decision taken together with the tutor, who was aware of the inherent risks. For enucleation, the animal was anesthetized with 0.035 mg/kg of acepromazine (Acepran 0.2% IM) and 0.3 mg/kg of morphine (Dimorphine 10 mg/ml IM), with induction of 2 mg/kg of propofol (Diprivan 200 mg/20 ml IV) and 1.5 mg/kg ketamine (Ketamine 10% IV). Extraconal retrobulbar block with 0.1 ml/kg of 2% S/V lidocaine per point of block and maintenance with isoflurane.

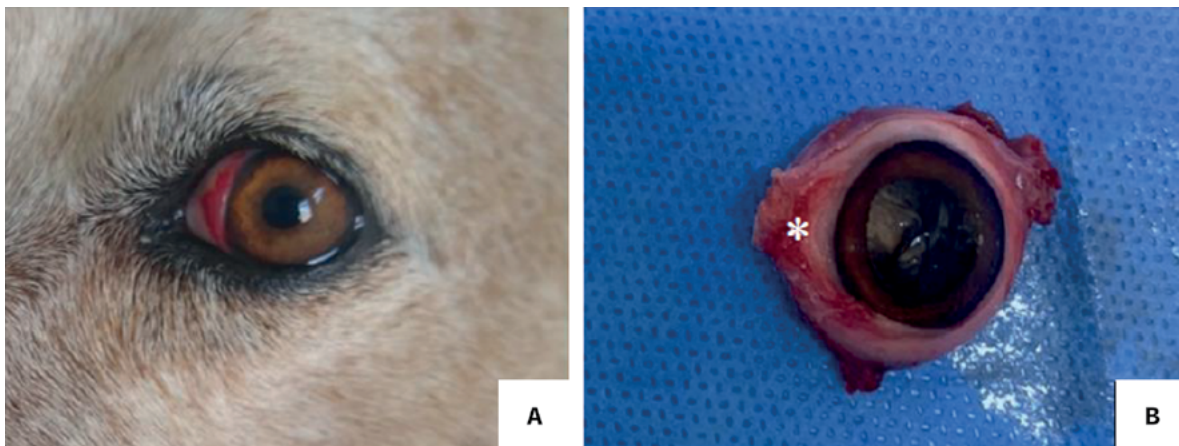
The LE was removed by enucleation and the surgical sample was sent for histopathological analysis. Post-operatively, meloxicam 0.2 mg/kg, SID, IV (Maxicam 0.2%) was administered; dipyron 25 mg/kg, TID, IV

(Dipyron 500 mg/ml); and enrofloxacin 4 mg/kg, SID, IV (10% Zelotril). The patient was kept under observation for 24 hours for medical follow-up and analysis of possible complications. At the end of this period, she was referred to finish the treatment at home and with the use of an Elizabethan collar for 10 days. Dipyron monohydrate (500 mg/ml) was prescribed (10 drops PE, BID, 4 consecutive days); meloxicam (0.1 mg/kg; 1 tablet SID, PO, 4 consecutive days); enrofloxacin (50 mg/kg; 1 tablet PE, SID, 5 consecutive days). Constant monitoring and new tests were recommended for follow-up 3 months after enucleation.

The surgical sample was sent for histopathological analysis, and an eyeball measuring 2.5 x 2.5 x 2.0 cm was sent, with a taut elastic consistency. Nodule in conjunctiva measuring 0.4 cm in diameter, irregular surface, soft consistency. The cuts have a solid, homogeneous surface, with a light brown color. Eyeball measuring 2.5 x 2.5 x 2.0 cm, with a taut-elastic consistency. In the sections, there were no macroscopic changes (Figure 2).

Regarding the nodule, we found a proliferation of neoplastic cells, formed by vascular spaces, occupied by blood and delimited by immature endothelial cells. The process demonstrates unbounded, unencapsulated

Figure 2. Location of the tumor mass in the patient's left eye. Note the distribution at the medial level, close to the nictitating membrane, with an irregular and hemorrhagic appearance (A). Location of conjunctival hemangiosarcoma (asterisk) in an eyeball measuring 2.5 x 2.5 x 2 cm, with the surface scraped due to the collection of a fragment for the first histopathological analysis (B)



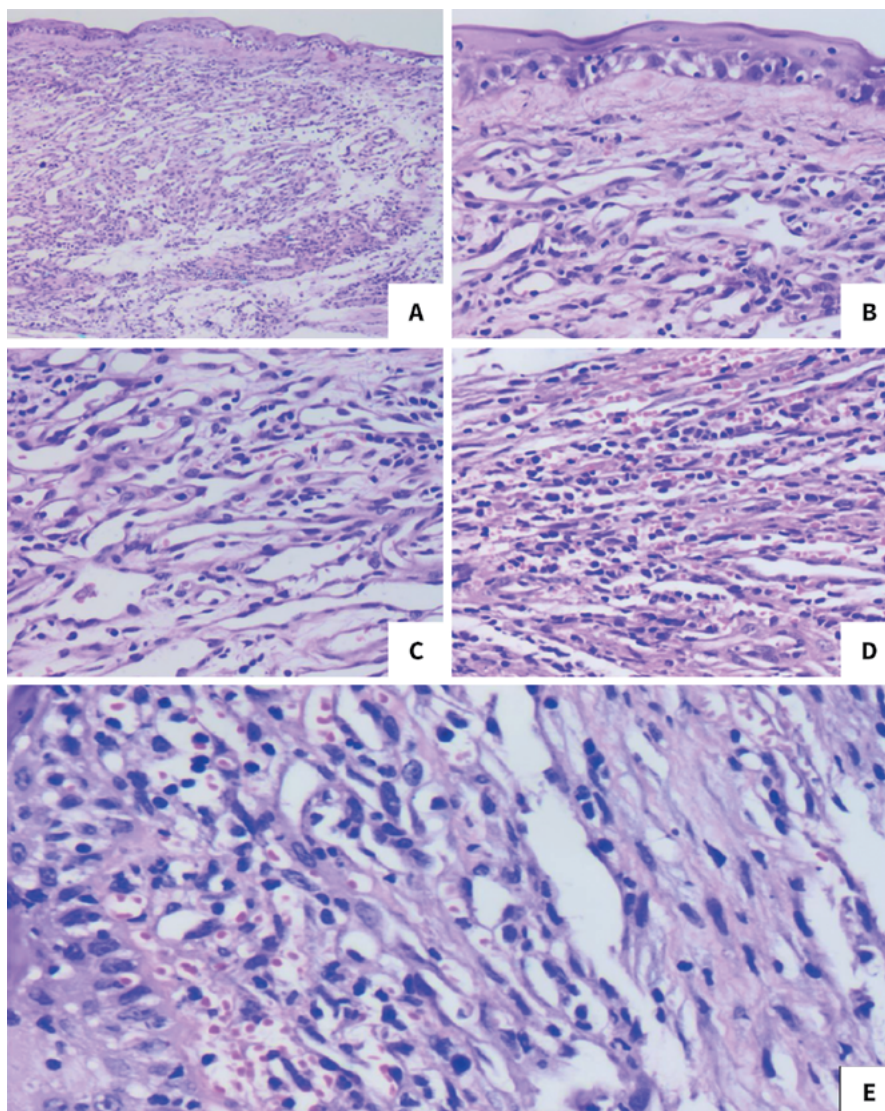
growth and is supported by discrete fibrous connective tissue. The cells have unbounded cytoplasm, with nuclei ranging from ovoid to round, normochromic, and small nucleoli. Moderate anisocytosis and anisokaryosis and one mitosis in 10 higher power fields (400x, 2.37 mm²). There is also a moderate multifocal lymphoplasmacytic infiltrate associated with edema and moderate mucosal degeneration. The eyeball showed slight peripheral cystic degeneration in the ora serrata

of the retina, with other intraocular structures without histopathological changes. The surgical margins were narrow (Figure 3).

DISCUSSION

HSA are serious neoplasms often associated with vascularized regions (2, 3), with the splenic parenchyma

Figure 3. Histopathological characterization of primary conjunctival hemangiosarcoma, HE (A-E). The presence of neoplastic cells, composed of vascular spaces, endothelial cells and blood vessels is observed. Presence of fibrous connective tissue, non-capsular appearance, variability of nuclei and anisokaryosis. Presence of lymphoplasmacytic infiltrates, with edematous regions and moderate mucosal degeneration (400x, 2.37 mm²)



being one of the most frequent places (5, 7). However, the presence of these tumors in ocular regions is less frequent, and there are few reports in the regions of the conjunctiva, eyelids, and third eyelid gland (11-14). Besides dogs, ocular HSA has been reported in cats, especially at the corneal level, with the presence of lymphoplasmacytic infiltrate and recurrent appearance (14). It is believed that UV rays (ultraviolet radiation) may be associated with the appearance of HSA; however, the study developed by Richardson and Deykin (2) could not consider UV as a risk factor (12).

According to Pirie et al. (15) tumors of vascular origin, primarily of the conjunctiva such as hemangioma or hemangiosarcoma, are less frequent. However, in the present report, the patient was diagnosed with conjunctival hemangiosarcoma, demonstrating that, although infrequent, these tumors can occur. The epidemiological pattern of HSA is associated with higher detection in dogs (8), with no reports of sexual predisposition (1, 5). Regarding the age range, dogs between 8-13/14 years can be considered the most affected (1,16). The patient in the present case was 8 years old, corroborating the data found by Camboim et al. (1) and Paiva et al. (16). Labrador, Golden Retriever and German Shepherd dogs are at greater risk for developing HSA (7). Nevertheless, dogs of other breeds can also be affected (17,18), as seen in the present report.

The clinical symptoms presented by the animals affected with HSA are variable and dependent on some factors such as the region of origin of the tumor; the capacity and existence of metastatic processes, and tumor disruption, among others (8,10). The most common clinical signs associated with HSA are lethargy, weakness, prostration, vomiting, decreased body condition score, anemia and manifestations of hypovolemia, pale mucous membranes, increased capillary refill time, abdominal distension and pain (3, 7, 19-22). In the present report, the patient had no clinical changes, and the parameters were all within the standard for the species, although the owner noticed the presence of small hemorrhages in the affected ocular region.

The diagnosis of HSA is based on the set of information obtained through clinical, laboratory and imaging tests, the definitive being through cytological and histopathological analyzes (1, 6-8, 23). In the present report, the patient was diagnosed with hemangiosarcoma through a combination of available diagnostic options. The general clinical and ophthalmological exams allowed the observation of the hemorrhagic mass in the LE, providing the management of the case and the determination of possible differential diagnoses. For Boo et al. (14), hemangiomas and granulation tissue are considered an example of possible differential diagnoses. Although laboratory tests did not show significant changes, they were able to provide important information about the patient's systemic health.

Neoplasms derived from HSA can incite the presence of metastases in other regions (8). For such confirmation, radiographic examinations provide important information about the presence of metastatic processes. According to Griffin et al. (8), HSA are aggressive tumors, with high and rapid metastatic capacity, a fact that can be associated with vascular irrigation. In the present report, the patient, after being diagnosed with conjunctival hemangiosarcoma, underwent a radiographic examination to search for possible metastases. However, the ventrodorsal projection did not show the presence of alterations suggestive of metastatic processes.

Among the diagnostic methods that present greater reliability in diagnostic determination, fine-needle aspiration cytology and histopathological examination stand out. Cytology in these cases makes it possible to analyze the cells present in the neoplasms to guide the clinical case. The histopathological examination allows the macro and microscopic characterization of the samples sent for analysis to assist in the diagnosis and management of the case. The tumor pattern of HSA is variable, it can be macroscopically characterized by initially single masses (8), with a non-uniform appearance, absence of a fibrous capsule, friable, with risk of rupture and blood leakage (24,25). For Griffin

et al. (8), HSA can be arranged in a multifocal aspect in the affected organ or sparse in the metastatic form.

In the histopathological analysis of HSA, it is possible to note the presence of intense pleomorphism, a cellular pattern composed of vast chromatin and abundant cytoplasm (7). The dimensions and aspects of the HSA may vary with chronicity and may become firm and close in color from red to gray (23). At the histopathological analysis of the sample collected and sent to the laboratory, the patient presented: proliferating neoplastic cells, with the presence of vascular spaces filled with blood; irregular and unmarked growth, not wrapped by capsule and with connective tissue, anisokaryosis and anisocytosis; lymphoplasmacytic infiltrate, and mucosal degeneration and swollen regions.

Therapeutic management can be performed after tumor staging, and chemotherapy should be carefully evaluated (8,16,26). Tumor excision may be an option to be considered during the therapeutic determination, although it is necessary to pay attention to the compromised state of the surgical margins (8). In addition, other therapies have been studied, such as the use of metronomic chemotherapy with immunomodulatory function, cyclooxygenase 2 (COX-2) blockers, electrochemotherapy, and angiogenesis inhibitors (16).

In the present report, the patient presented a tumor in the medial region of the eye, encompassing part of the conjunctiva, and after the first histopathological analysis (fragment of the lesion), there was a diagnosis of HSA with compromised margins. Thus, the decision to perform enucleation was made together with the owner. According to Boo et al. (14), the enucleation option is a curative treatment, without evidence of local recurrences and metastases. According to Yamamoto et al. (27), complete surgical removal of the tumor may offer better quality of life and therapeutic efficacy.

In a study carried out by Richardson & Deykin (2) with ocular tumors (hemangiomas and HSA), in 59 cases (59/60) the animals underwent surgical resection as an initial therapeutic decision, with a success rate of 90%.

According to Scherrer et al. (28), the complete surgical excision may be related to improved prognosis in horses. For Pirie & Dubielzig (12), cases of tumor remission after excision may occur. In reports described by Cazalot et al. (29) and Storms et al. (30), no recurrences were found after complete tumor removal. However, Boo et al. (13) report tumor recurrence after incomplete excision associated with cryotherapy.

CONCLUSION

HSA are neoplasms of high importance, with uncommon reports in places such as the conjunctival region. However, the early diagnosis of these neoplasms allows the early establishment of pharmacological and/or surgical treatments to guarantee the patient's quality of life. The complete removal of the eye was the decision taken by the professionals responsible for the case and so far, there have been no recurrences.

DATA AVAILABILITY STATEMENT

The data that support the findings of this study are available from the corresponding author, FGS, upon reasonable request.

CONFLICT OF INTEREST

The authors report no conflicts of interest. The authors alone are responsible for the content and writing of this article.

REFERENCES

1. Camboim AS, Benvenuti MEM, Oliveira EL, Vaz AFM, Silva NMR, Dantas AFM, et al. Manifestation of paraneoplastic syndrome in a dog with cutaneous hemangiosarcoma: case report. *Braz J Vet Med.* 2017;39(2):126-32. <https://doi.org/10.29374/2527-2179.bjvm025016>

2. Richardson S, Deykin AR. Surgical treatment of conjunctival hemangioma and hemangiosarcoma: a retrospective study of 52 dogs. *Vet Ophthalmol.* 2021;24(5):432-41. <https://doi.org/10.1111/vop.12921>
3. Kim J-H, Graef AJ, Dickerson EB, Modiano JF. Pathobiology of Hemangiosarcoma in Dogs: Research Advances and Future Perspectives. *Vet Sci.* 2015;2(4):388-405. <https://doi.org/10.3390/vetsci2040388>
4. Guberman UC, Merlini NB, Perches CS, Fonzar JF, Sereno MG, Mamprim MJ, Ranzani JJT, Brandão CVS. Corneal hemangiosarcoma in a dog. *Arq Bras Med Vet Zootec.* 2015;67(2):343-6. <https://doi.org/10.1590/1678-7685>
5. Soares NP, Medeiros AA, Szabo MPJ, Guimaraes EC, Fernandes LG, Santos TR. Hemangiomas and Hemangiosarcomas in dogs: a retrospective study of 192 cases (2002-2014). *Cienc Anim Bras.* 2017;18:1-10. <https://doi.org/10.1590/1089-6891v18e-30889>
6. Pigatto JAT, Albuquerque L, Voll J, Driemeier D. Hemangiosarcoma of the third eyelid in a dog. *Acta Sci Vet.* 2015;43:91. Available from: https://www.ufrgs.br/actavet/43-suple-1/CR_91.pdf
7. Freitas J, Yi LC, Forlani GS. Canine hemangiosarcoma: review. *Pubvet.* 2019;13(8):1-9. <https://doi.org/10.31533/pubvet.v13n8a389.1-9>
8. Griffin MA, Culp WTN, Rebhun RB. Canine and feline hemangiosarcoma. *Vet Record.* 2021;189(9):e585. <https://doi.org/10.1002/vetr.585>
9. Hendrick MJ. Mesenchymal Tumors of the Skin and Soft Tissues. In: *Tumors in Domestic Animals.* 5th ed. Nova Jersey: Wiley-Blackwell; 2017. p. 142-75. <https://doi.org/10.1002/9781119181200.ch5>
10. Mulin C, Clifford CA. Histiocytic Sarcoma and Hemangiosarcoma Update. *Vet Clin North Am Small Anim Pract.* 2019;49(5):855-79. <https://doi.org/10.1016/j.cvsm.2019.04.009>
11. Multari D, Vascellari M, Mutinelli F. Hemangiosarcoma of the third eyelid in a cat. *Vet Ophthalmol.* 2002; 5(4):273-6. <https://doi.org/10.1046/j.1463-5224.2002.00254.x>
12. Pirie CG, Dubielzig RR. Feline conjunctival hemangioma and hemangiosarcoma: a retrospective evaluation of eight cases (1993–2004). *Vet Ophthalmol.* 2006;9(4):227-31. <https://doi.org/10.1111/j.1463-5224.2006.00472.x>
13. Hartley C, Ladlow J, Smith KC. Cutaneous haemangiosarcoma of the lower eyelid in an elderly white cat. *J Feline Med Surg.* 2007; 9(1):78-81. <https://doi.org/10.1016/j.jfms.2006.05.011>
14. Boo G, Caruso KA, Whittaker CJ, Smith JS, Lurie D, Nguyen S. Recurrent corneal hemangiosarcoma in a cat with subsequent extension into the orbit. *Vet Ophthalmol.* 2021;24(4):408-13. <https://doi.org/10.1111/vop.12868>
15. Pirie CG, Knollinger AM, Thomas CB, Dubielzig RR. Canine conjunctival hemangioma and hemangiosarcoma: a retrospective evaluation of 108 cases (1989-2004). *Vet Ophthalmol.* 2006;9(4):215-26. <https://doi.org/10.1111/j.1463-5224.2006.00471.x>
16. Paiva FN, Oliveira LC, Ferrari BS, Torquato LFB, Araújo DCC, Costa TS, Fernandes JI. Multimodal therapy in the treatment of canine cutaneous hemangiosarcoma. *Cienc Anim.* 2020;30(3):155-62.
17. Story AL, Wavreille V, Abrams B, Egan A, Cray M, Selmic LE. Outcomes of 43 small breed dogs treated for splenic hemangiosarcoma. *Vet Surgery.* 2020;49(6):1154-63. <https://doi.org/10.1111/vsu.13470>
18. Flores MM, Panziera W, Kommers GD, Irigoyen LF, Barros CSL, Figuera RA. Aspectos epidemiológicos e anatomopatológicos do hemangiossarcoma em cães: 40 casos (1965-2012). *Pesquisa Veterinária Brasileira.* 2012;32(12):1319-28. <https://doi.org/10.1590/S0100-736X2012001200017>
19. Smith AN. Hemangiosarcoma in dogs and cats. *Vet Clin North Am Small Anim Pract.* 2003;33(3):533-52. [https://doi.org/10.1016/S0195-5616\(03\)00002-0](https://doi.org/10.1016/S0195-5616(03)00002-0)
20. Culp WT, Weisse C, Kellogg ME, Gordon IK, Clarke DL, May LR, Drobotz KJ. Spontaneous hemoperitoneum in cats: 65 cases (1994–2006). *J Am Vet Med Assoc.* 2010;236(9):978-82. <https://doi.org/10.2460/javma.236.9.978>
21. Hammond TN, Pesillo-Crosby SA. Prevalence of hemangiosarcoma in anemic dogs with a splenic mass and hemoperitoneum requiring a transfusion: 71 cases (2003–2005). *J Am Vet Med Assoc.* 2008;232(4):553-8. <https://doi.org/10.2460/javma.232.4.553>

22. Boston SE, Higginson G, Monteith G. Concurrent splenic and right atrial mass at presentation in dogs with HSA: a retrospective study. *J Am Anim Hosp Assoc.* 2011;47(5):336-41. <https://doi.org/10.5326/JAAHA-MS-5603>
23. Andrade E, Dalegrave S, Andrade J, Flecke LR. Unilateral renal hemangiosarcoma in a dog: Case report. *Pubvet.* 2021; 15:1-7. <https://doi.org/10.31533/pubvet.v15n05a817.1-7>
24. Pascoli AL, Mendonça APR, Lira RN, De Nardi AB, Filho NPR. Primary conjunctival-sclero-corneal hemangiosarcoma in a feline: Case report. *Medvep.* 2014; 12(40): 214-6. Available from: <https://pesquisa.bvsalud.org/portal/resource/pt/vti-10689?lang=en>
25. Souza RG, Kassab S, Barroso RMV, Oliveira RS, Simplício VA. Advancement flap for correction of hemangiosarcoma in the penile region of a dog: case report. *Arq Cienc Vet Zool UNIPAR.* 2020; 23(2):e2308. <https://doi.org/10.25110/arqvet.v23i2cont.2020.7962>
26. Faroni E, Sabattini S, Guerra D, Iannuzzi C, Chalfon C, Agnoli C, Stefanello D, Polton G, Ramos S, Aralla M, Ciaccini R, Foglia A, Okonji S, Marconato L. Timely adjuvant chemotherapy improves outcome in dogs with non-metastatic splenic hemangiosarcoma undergoing splenectomy. *Vet Comp Oncol.* 2023;1-8. <https://doi.org/10.1111/vco.12875>
27. Yamamoto S, Hoshi K, Hirakawa A, Chimura S, Kobayashi M, Machida N. Epidemiological, clinical and pathological features of primary cardiac hemangiosarcoma in dogs: a review of 51 cases. *J Vet Med Sci.* 2013;75(11):1433-41. <https://doi.org/10.1292/jvms.13-0064>
28. Scherrer NM, Lassaline M, Engiles J. Ocular and periorbicular hemangiosarcoma in six horses. *Vet Ophthalmol.* 2018;21(4):432-7. <https://doi.org/10.1111/vop.12529>
29. Cazalot G, Regnier A, Deviers A, Serra F, Lucas MN, Etienne CL, Letron IR. Corneal hemangiosarcoma in a cat. *Vet Ophthalmol.* 2011;14:117-21. <https://doi.org/10.1111/j.1463-5224.2011.00928.x>
30. Storms G, Naranjo C, Grauwels M. Concurrent squamous cell carcinoma and hemangiosarcoma in the cornea of a cat. *Vlaams Diergen Tijds.* 2016;85(1):31-5. <https://doi.org/10.21825/vdt.v85i1.16405>